
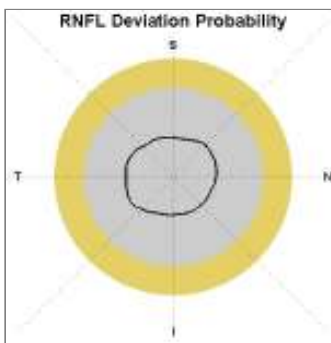
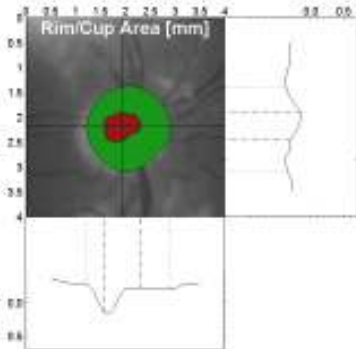
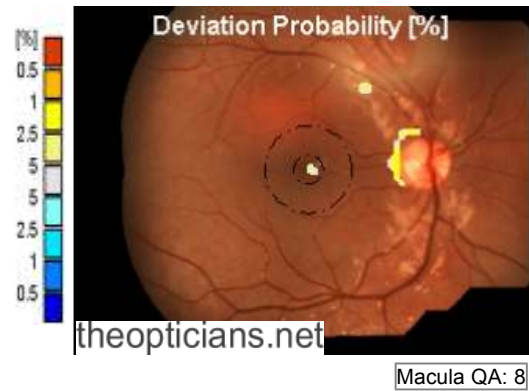
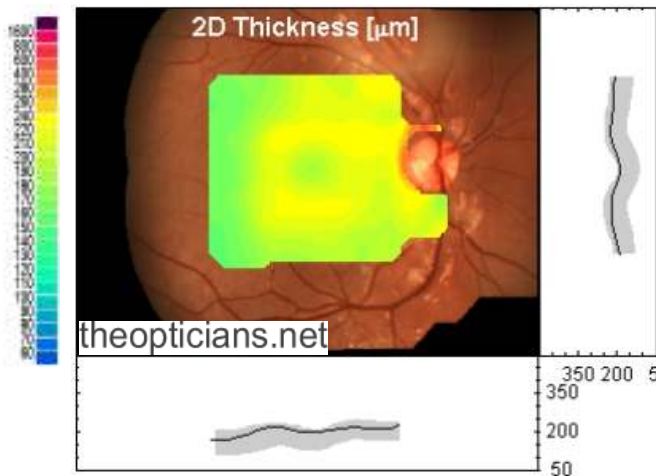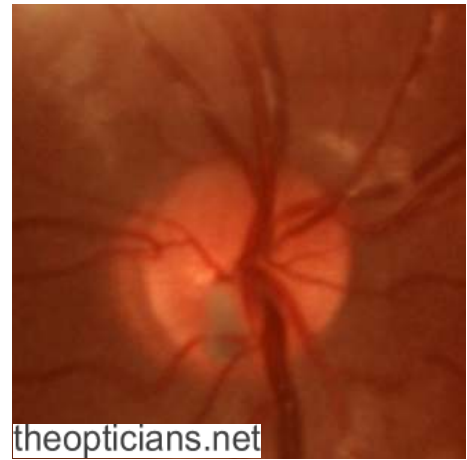
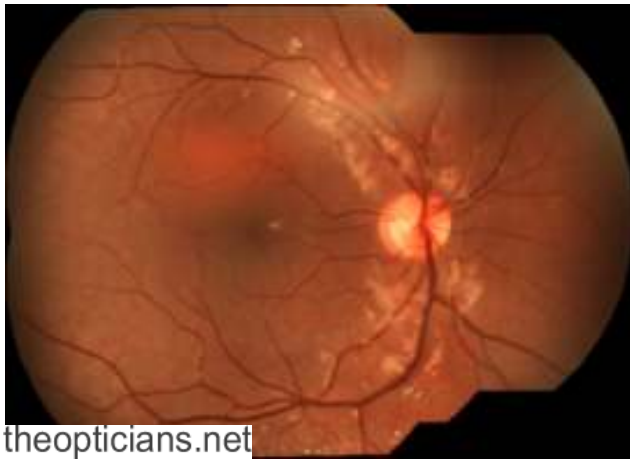

Name: John Smith
Patient ID: 183

OD

Examination Date: Jan 1, 2009

Session: 20090101_QUI_a
Date of Birth: Mar 5, 1975



Disc QA: 8

Index	Value	Prob.
Disc Diameter	1.71 [mm]	NA
Vertical C/D	0.33	NA
Cup shape Indicator	0.38	NS

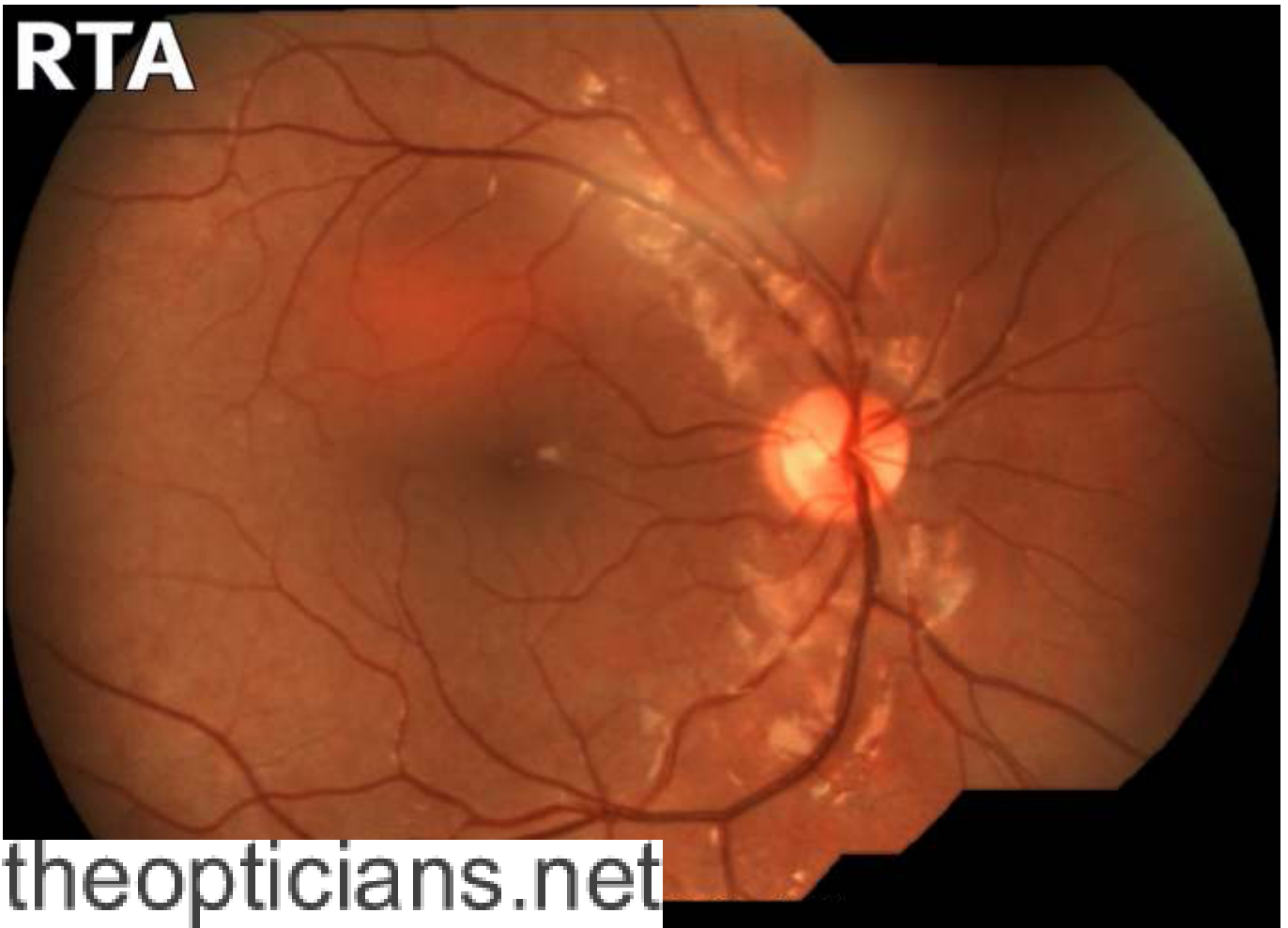Remarks RTA 3 Findings are: Thickness **WNL*** RNFL **WNL***
Fundus Image should be evaluated separately.

* WNL=Within Normal Limits
* ONL=Outside Normal Limits

Name: _____

Signature: _____

RTA



theopticians.net